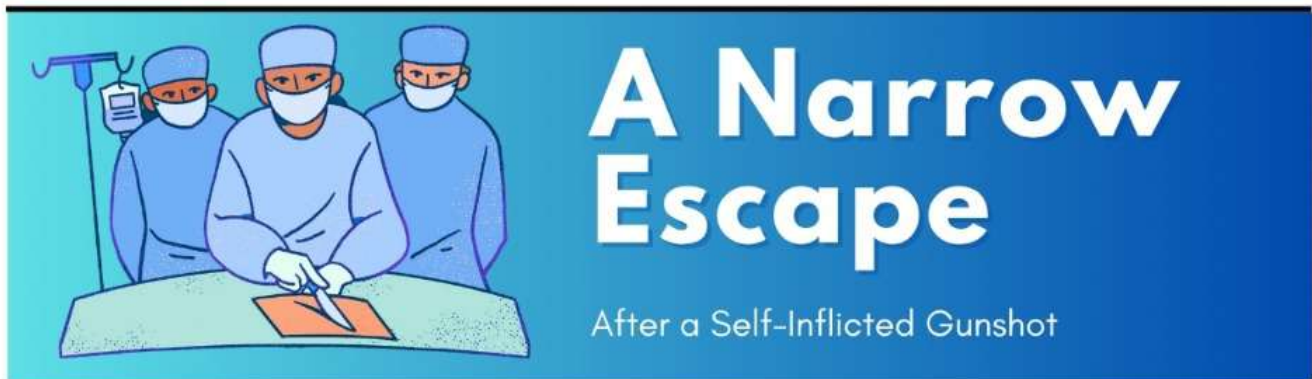
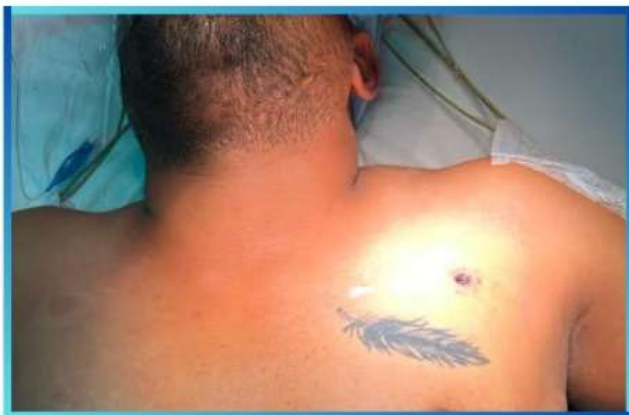

INDORE • 2025 • VOL 14



A 28-year man walked in casualty and gave history of self-inflicted gunshot to his left side chest. Surprisingly - conscious and alert.

Admitted and investigated - The bullet had fractured four ribs and lodged close to his lungs and heart, missed every vital organ - a near impossible escape.



Under the expert leadership of Dr. Akshay Sharma (Consultant - General & Colorectal Surgeon), taken for surgery - a 5 cm posterior chest incision was made to extract the bullet lodged closed to pleura without injuring the lung and pericardium.

Seven to eight smaller fragments were also retrieved with precision, with no bleeding/no lung collapse/no chest drain required - a rare surgical outcome.

The patient recovered exceptionally well - no ICU stay, no ventilator and was discharged in just three days.

Gunshot injuries are unpredictable, often causing hidden internal damage. In this case, the bullet's path was dangerously close to vital organs, but precision and timing made all the difference. Our goal was complete fragment removal without added trauma, preventing risks like heavy metal toxicity/sepsis.

Dr. Akshay Sharma
Consultant - General & Colorectal Surgeon
Vishesh Jupiter Hospital, Indore

